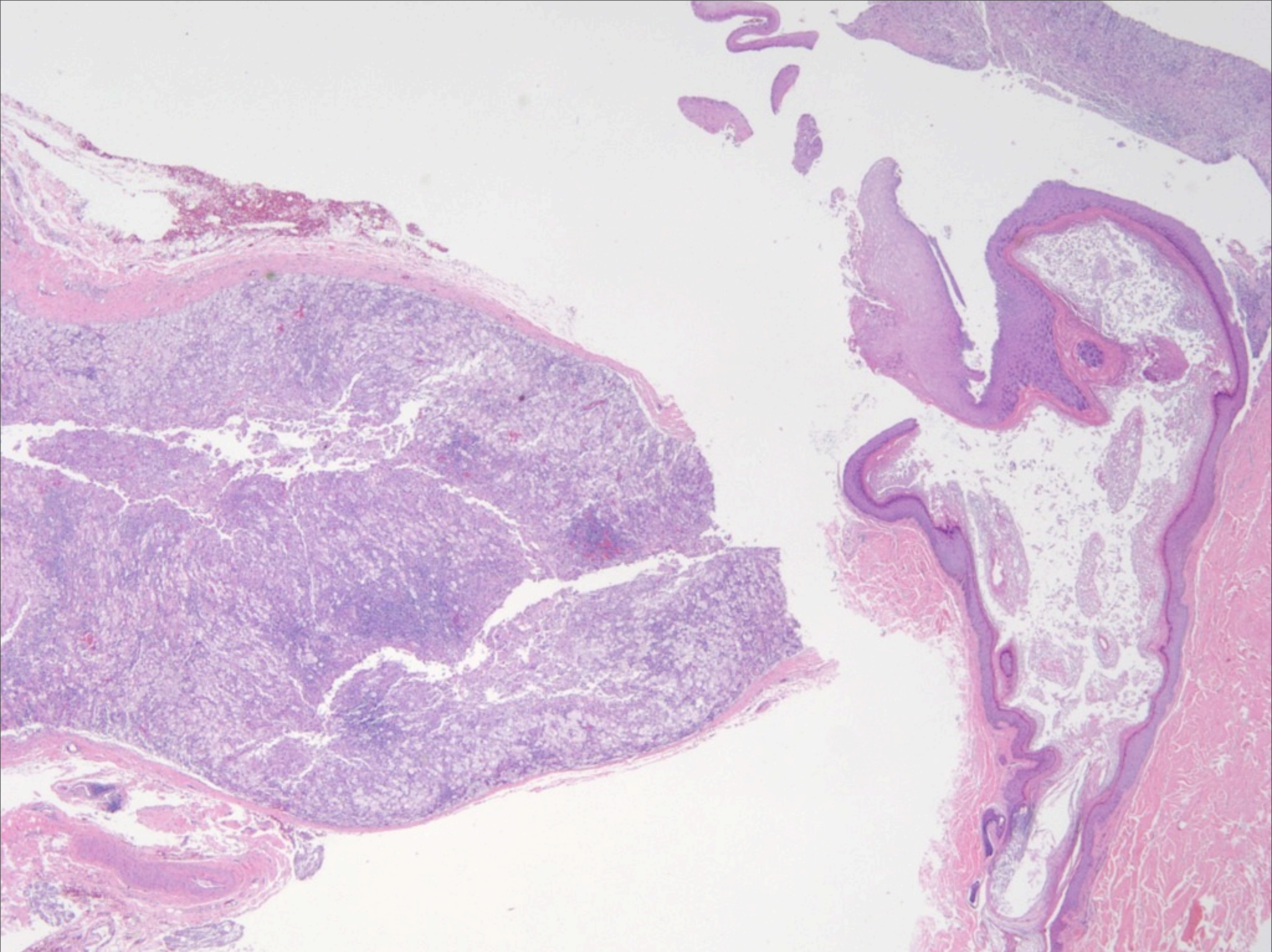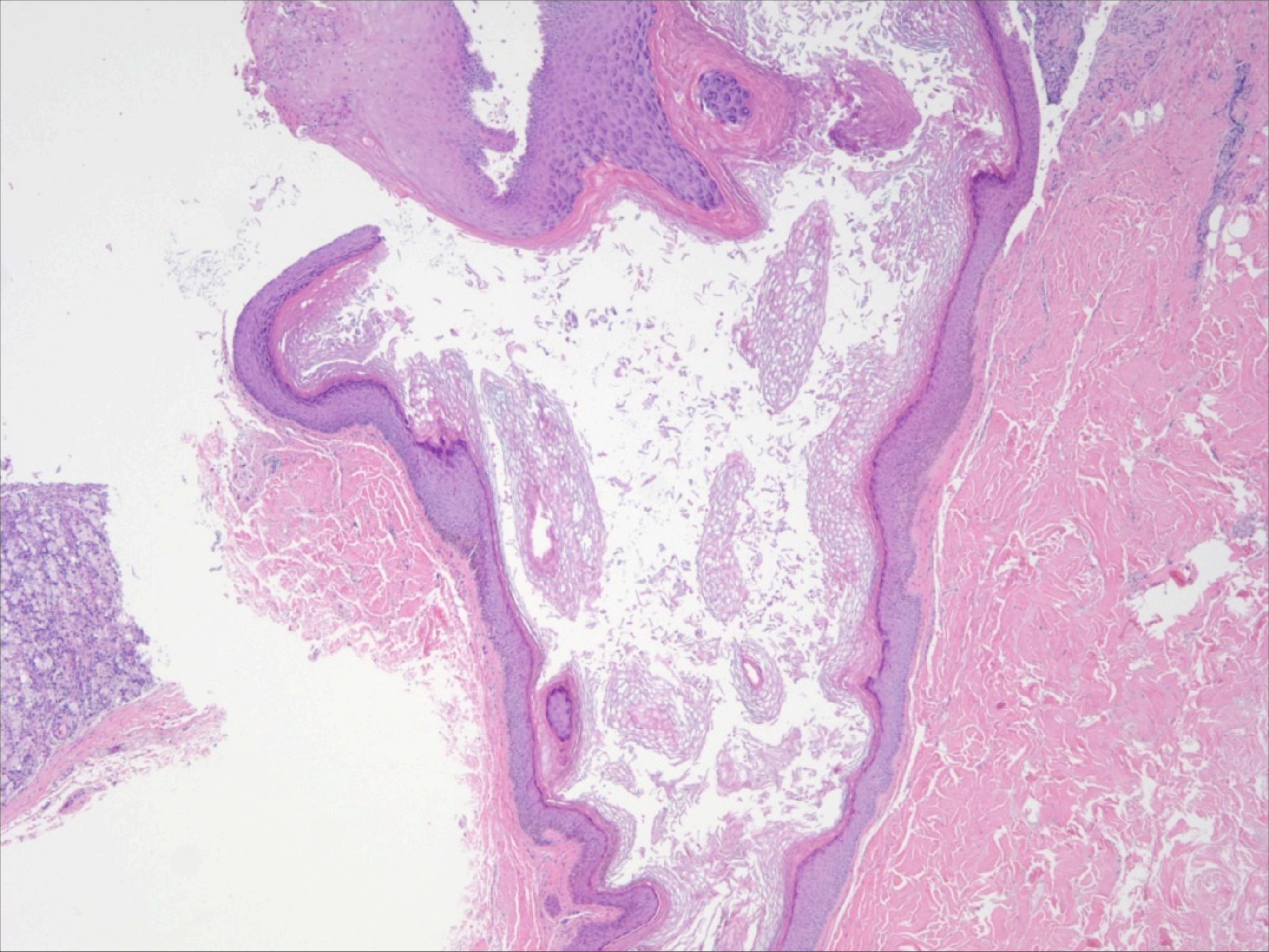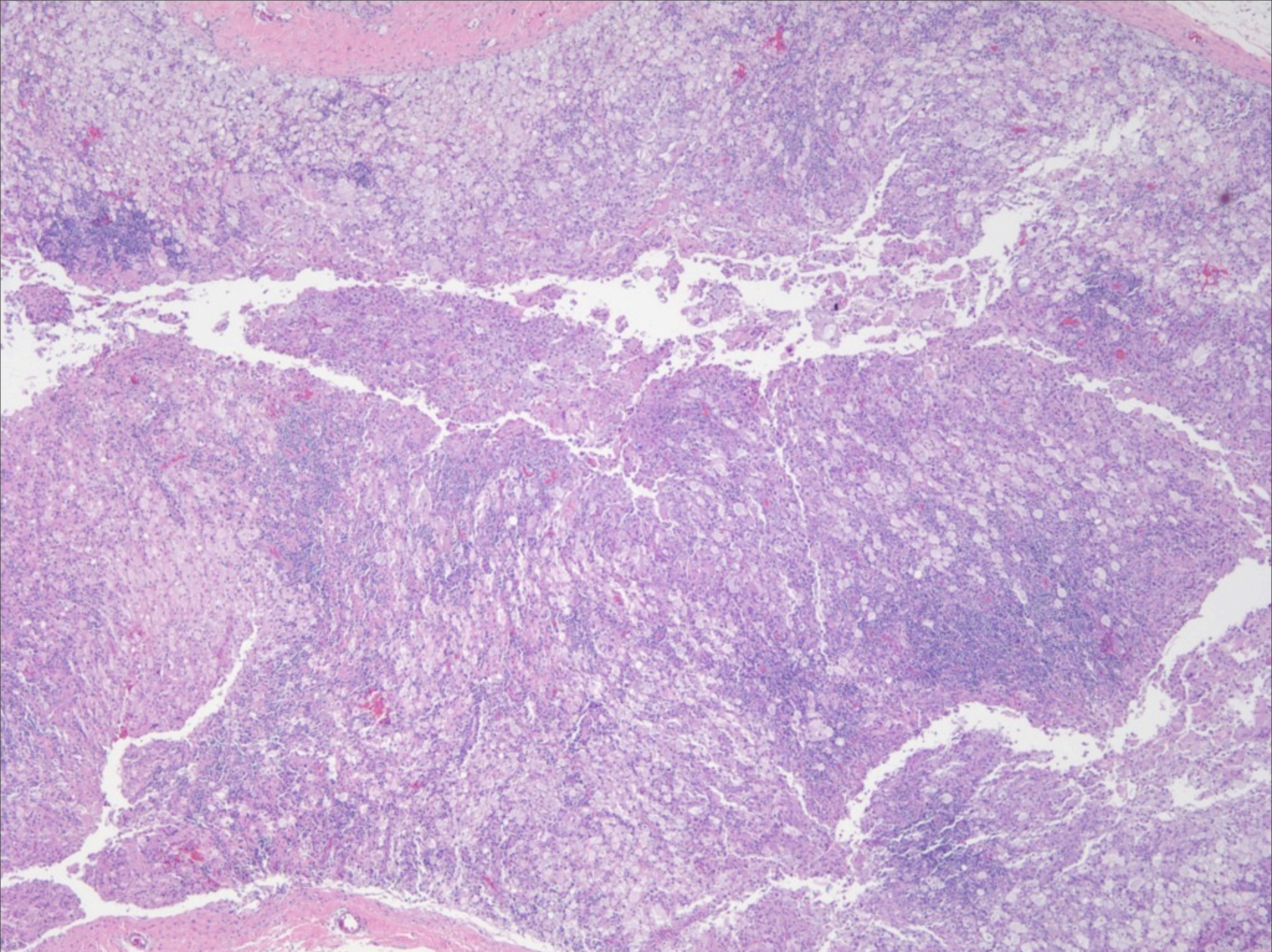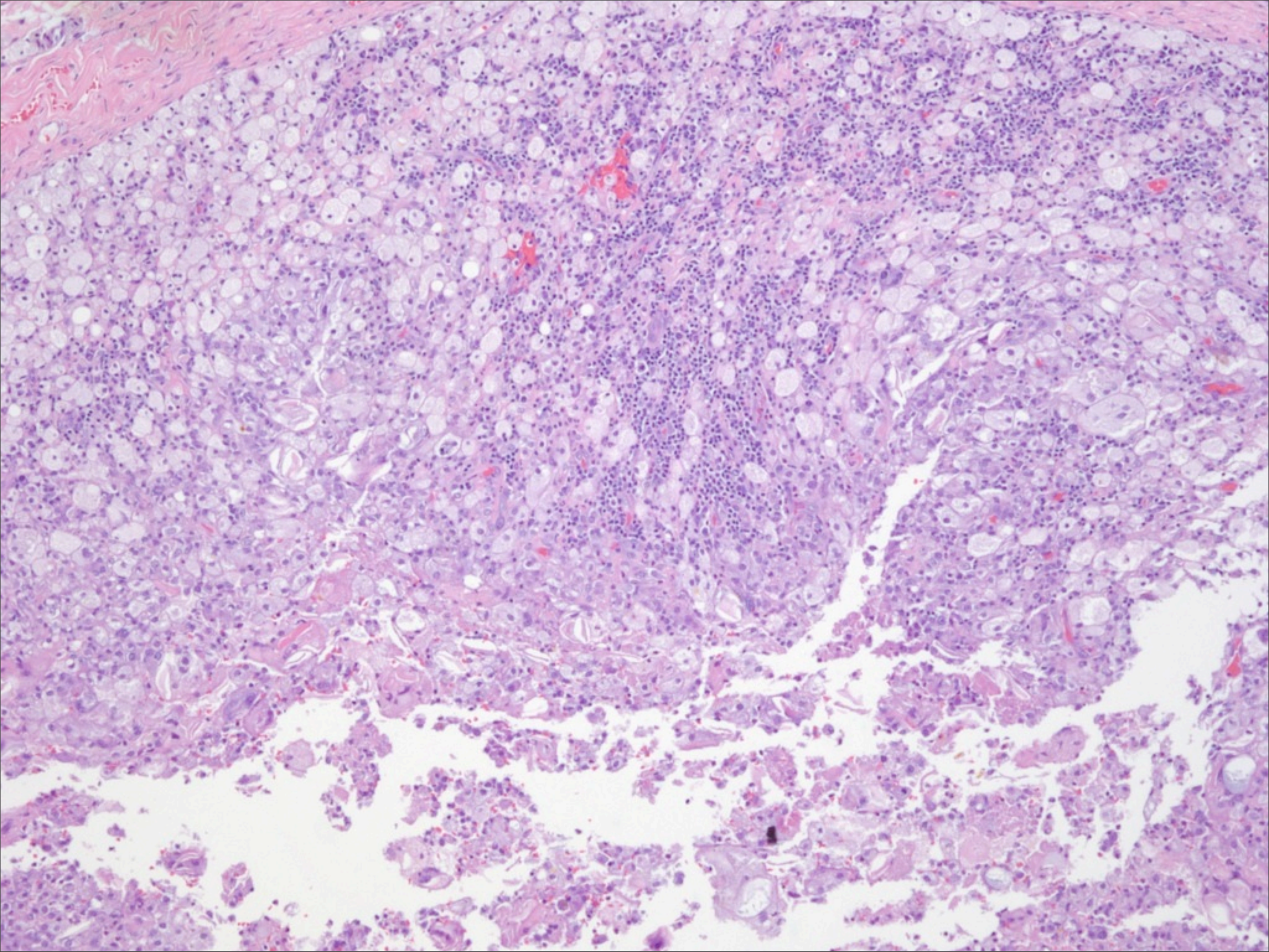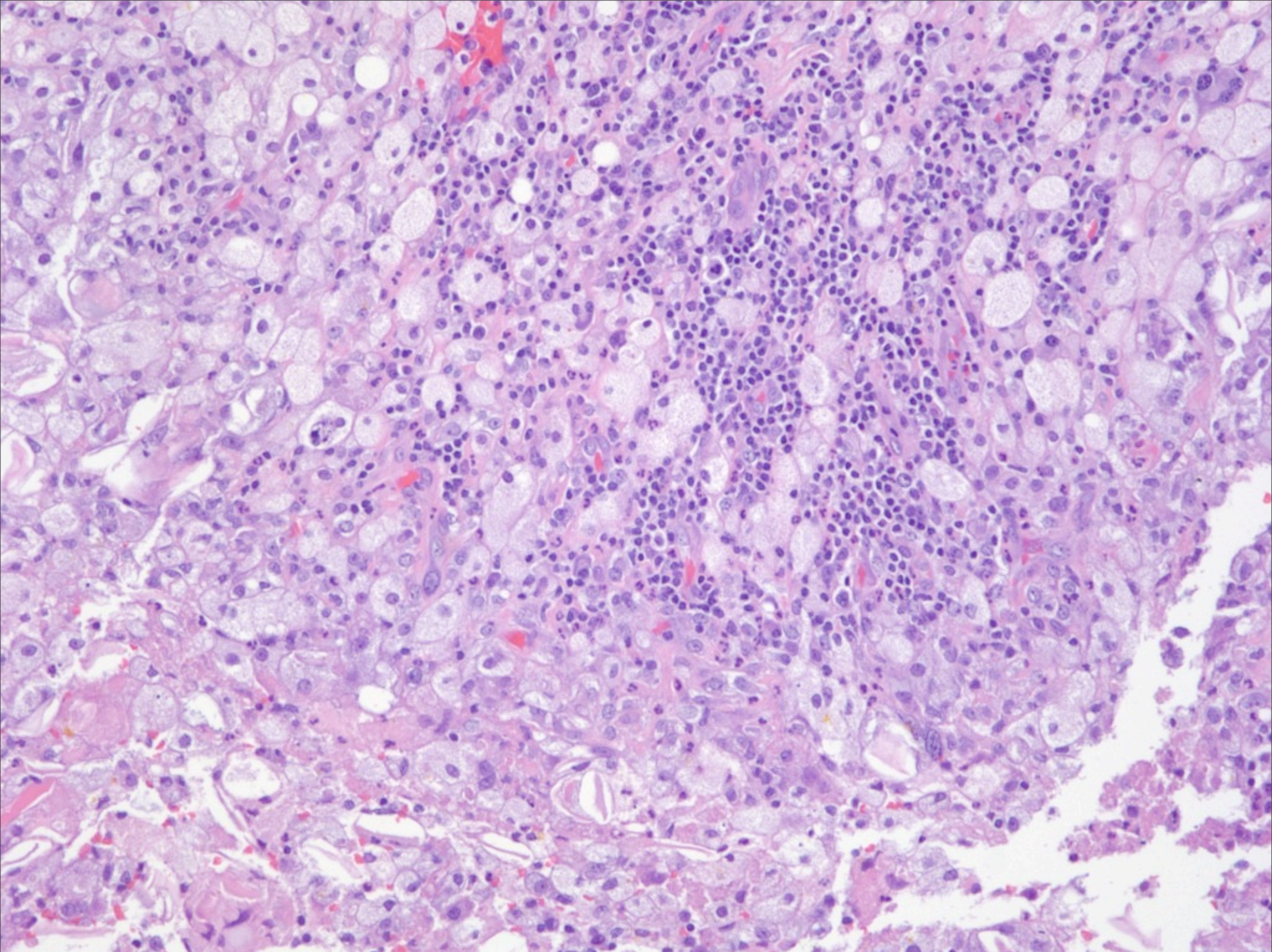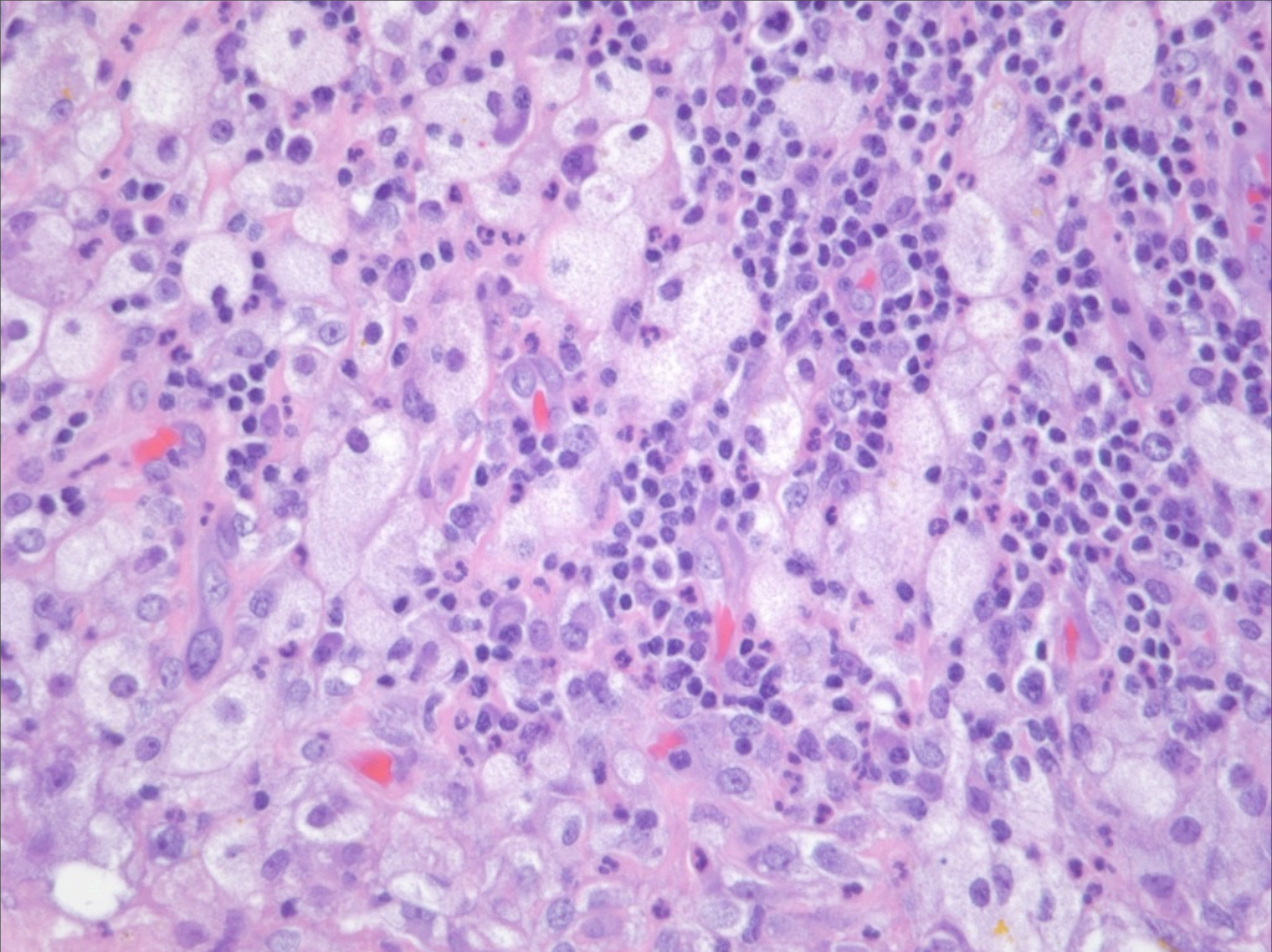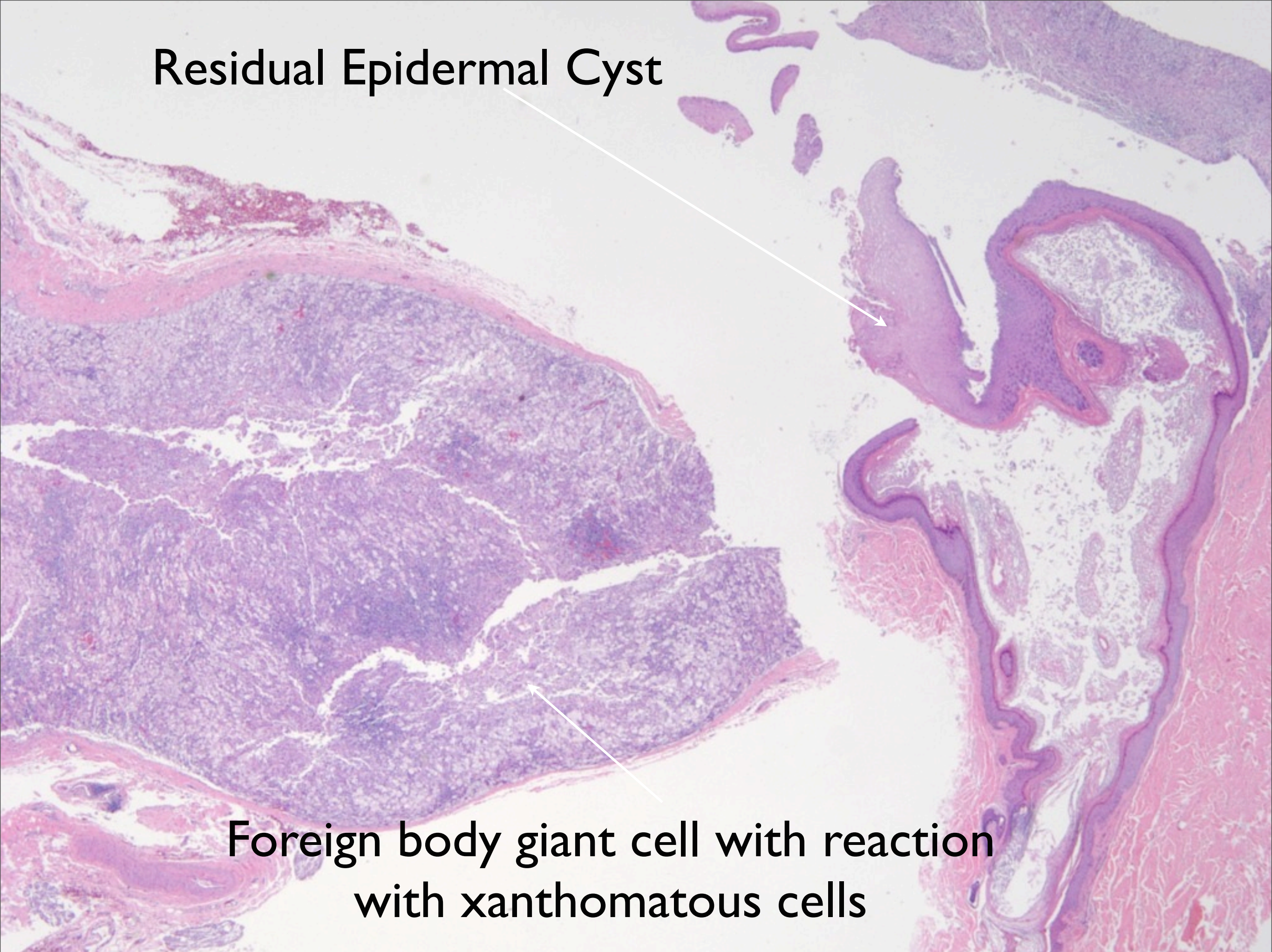


Epidermal Inclusion Cyst with Rupture

Residual Epidermal Cyst



Foreign body giant cell with reaction
with xanthomatous cells